

Hypersensitivity to titanium: Clinical and laboratory evidence

Kurt MÜLLER¹, MD & Elizabeth VALENTINE-THON², PhD

¹ Practice for Dermatology and Environmental Medicine, Isny, Germany

² Department of Immunology, Laboratory Center Bremen, Bremen, Germany

Correspondence to: Dr. Kurt E. Müller, MD
Practice for Dermatology and Environmental Medicine
Scherrwiesenweg 16
88316 Isny, GERMANY
TEL: +49 7562 55051; FAX: +49 7562 55052
EMAIL: info@docmueller-isny.de

Submitted: October 13, 2006

Accepted: November 17, 2006

Key words: titanium; hypersensitivity; MELISA®; dental implants; endoprostheses

Neuroendocrinol Lett 2006;27(Suppl 1):31-35 PMID: 17261997 NEL270706A11 ©Neuroendocrinology Letters www.nel.edu

Abstract

OBJECTIVES: This study was carried out to investigate the potential of titanium to induce hypersensitivity in patients chronically exposed to titanium-based dental or endoprosthetic implants.

METHODS: Fifty-six patients who had developed clinical symptoms after receiving titanium-based implants were tested in the optimized lymphocyte transformation test MELISA® against 10 metals including titanium. Out of 56 patients, 54 were patch-tested with titanium as well as with other metals. The implants were removed in 54 patients (2 declined explantation), and 15 patients were retested in MELISA®.

RESULTS: Of the 56 patients tested in MELISA®, 21 (37.5%) were positive, 16 (28.6%) ambiguous, and 19 (33.9%) negative to titanium. In the latter group, 11 (57.9%) showed lymphocyte reactivity to other metals, including nickel. All 54 patch-tested patients were negative to titanium. Following removal of the implants, all 54 patients showed remarkable clinical improvement. In the 15 retested patients, this clinical improvement correlated with normalization in MELISA® reactivity.

CONCLUSION: These data clearly demonstrate that titanium can induce clinically-relevant hypersensitivity in a subgroup of patients chronically exposed via dental or endoprosthetic implants.

Abbreviations & Units

CFS	– chronic fatigue syndrome
LTT	– lymphocyte transformation test
MCS	– multiple chemical sensitivity
MELISA®	– memory lymphocyte immunostimulation assay
SI	– stimulation index

Introduction

The use of titanium (Ti) in medicine and dentistry increased during the last three decades. Ti alloys have been widely used for dental implants, endoprostheses, pacemakers, stents, orthodontal brackets, and eyeglass frames. An oxide film is immediately formed on the surface of this highly reactive transition metal, and this has been claimed to result in good corrosion behavior and high biocompatibility [10]. Therefore, Ti has been considered to be particularly suitable for use in both dental and prosthetic implantation. Nevertheless, sporadic cases of intolerance have been reported [1, 3, 5, 13–15, 18, 19, 27–29, 31–33]. At the same time, no standard patch test for Ti has so far been developed, and positive reactions to Ti have therefore only rarely been demonstrated with skin testing [1, 13, 18]. Patch testing in general has been validated only for epidermal antigen contact, may itself induce sensitization of naive T lymphocytes, and is relevant primarily for detecting dermal effects of hypersensitivity (contact dermatitis) [12]. *In vitro* testing with the lymphocyte transformation test (LTT), on the other hand, can detect both dermally and non-dermally sensitizing allergens (e.g. beryllium [Be]). As an *in vitro* test, LTT cannot sensitize the patient. It has been used successfully to detect hypersensitivity leading to both local and systemic effects, for example those resulting from drug allergies [7, 16, 23, 34]. In addition, several groups have documented the sensitivity, specificity, reproducibility, and reliability of this approach for detecting metal sensitization, in particular in the optimized version of LTT called memory lymphocyte immunostimulation assay (MELISA®) [2, 6, 24, 25, 29–31]. Therefore, MELISA® was selected for investigating hypersensitivity to Ti in this study.

Material & MethodsPatients

Fifty-six patients (17 male, 39 female; mean age 53.8 years, range 14.3–84.1 years) were included in this study. All had developed health problems such as muscle, joint, and nerve pain, chronic fatigue syndrome (CFS), neuro-

logical problems, depression, multiple chemical sensitivity (MCS), dermatitis, and acne-like facial inflammation after receiving Ti-based dental and/or endoprosthetic implants (Table 1). Patients with other well-known diseases (polyarthritis, rheumatological disorders, diabetes, metabolic diseases, etc.) were excluded.

MELISA® testing

The MELISA® test was performed on all patients before and on 15 patients also after removal of the implants. MELISA® is a test method developed by Stejskal et al. [24] and validated by Valentine-Thon [29–31]. Patient lymphocytes were tested against titanium dioxide (TiO₂) and nine of the following metals, requested by the physician: Be, cadmium (Cd), chromium (Cr), cobalt (Co), copper (Cu), gold (Au), indium (In), inorganic mercury (HgCl₂), lead (Pb), nickel (Ni), palladium (Pd), platinum (Pt), and tin (Sn). A Stimulation Index (SI) was defined as the quotient of test counts per minute (cpm) and average negative control (background) cpm. SI ≥ 3 was considered positive (i.e. indicative of specific sensitization), SI ≥ 2 but < 3 ambiguous, and SI < 2 negative. For quality control, morphological analysis was additionally performed to confirm the presence of lymphoblasts in positive reactions and to exclude cytotoxicity in negative reactions.

Patch testing

Patch testing was performed on most (54) patients using the standard metal series from HAL Allergie GmbH (Düsseldorf, Germany) as well as for Ti (Titanium-IV-oxide 0.1% ointment) [13].

ResultsMELISA® testing

Of the 56 patients tested, 21 (37.5%) were positive to Ti (average SI = 6.3, range SI = 3.1 to 47.5), 16 (28.6%) were ambiguous to Ti (average SI = 2.4, range SI = 2.1 to 2.8), and 19 (33.9%) were negative to Ti (SI < 2). In addition, a total of 12 (21.4%) reacted to Ni (10 patch test positive), 8 (14.3%) to HgCl₂ (2 patch test positive), 6 (10.7%) to Cd, 3 (5.4%) to Au (all patch test negative), and 2 (3.6%) each to Pd (1 patch test positive), Pt, and Sn. In the Ti-negative group, 11 patients (57.9%) reacted to one or two other metals, primarily Ni (4 patients).

Morphological analysis confirmed the presence of lymphoblasts in all positive results as well as the presence of Ti-engorged macrophages in Ti-containing cultures

Table 1. Titanium-based dental or prosthetic implants in 56 patients.

Implant type	Number of patients
Dental implants	35
Endoprostheses	18
Gold alloys containing titanium	2
Orthodontic bracketing	1

One patient with both dental and endoprosthetic implants is included in the "Endoprostheses" group.

Morphological analysis of metal-induced lymphocyte proliferation in MELISA®

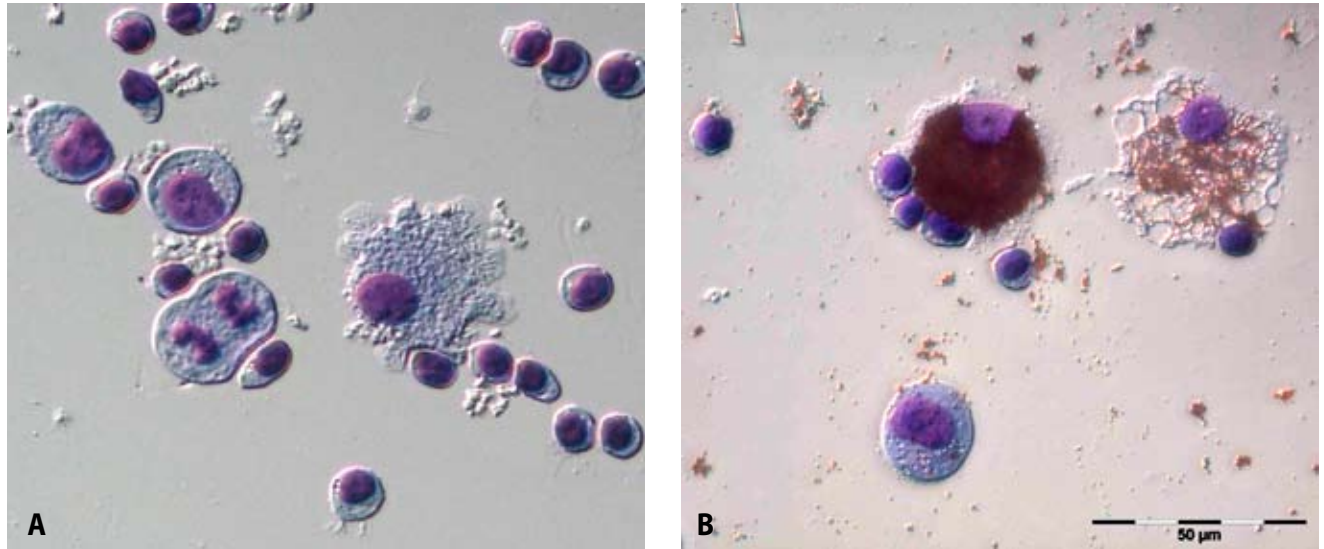


Figure 1. Morphological analysis of Ni-stimulated (A) and Ti-stimulated (B) patient lymphocytes after rapid differential haematology staining of cytopsin preparations of 5-day-old cell cultures.
 In A: three lymphoblasts (one in anaphase), one macrophage, and several resting lymphocytes visible.
 In B: one lymphoblast, two macrophages (one totally engorged with Ti particles), and a few resting lymphocytes visible.

(Fig. 1). None of the metal solutions were cytotoxic. Lymphocytes from all patients responded strongly ($SI > 30$) to stimulation by Pokeweed Mitogen as positive control.

Removal of the implants resulted in dramatic clinical improvement in all 54 cases (2 patients chose not to undergo the procedure). In the 15 patients retested in MELISA® following explantation, clinical improvement correlated with a normalization of Ti reactivity (average $SI = 1.5$, range $SI = 1.1$ to 2.6). Two typical cases are described below.

Patient 1 (Fig. 2) A 54-year-old man had Ti dental implants and 4 Ti screws in his cervical vertebra (due to an accident 1.5 years previously) and presented with CFS, cognitive impairment, Parkinson-like trembling, and severe depression. The severity of his symptoms precluded employment. MELISA® reactivity to Ti was

strongly positive ($SI = 47.5$). Patch testing to Ti was negative. Six months after removal of the dental implants and screws (2 of which were so corroded that the heads were separated from the bases), MELISA® reactivity to Ti became negative ($SI = 1.5$), and the patient's symptoms improved to such an extent that he was able to return to work.

Patient 2 (Fig. 3) Six months after being fitted with Ni-free Ti brackets spanning the front teeth in both the upper and lower jaw, a 14-year old girl developed inflammatory lesions of the face and jaw mimicking acne indurata. In addition, she complained of physical and mental exhaustion. She was previously completely healthy with no signs of acne. The typical local treatments for acne were ineffective. Endocrinological dysfunctions could be excluded. MELISA® testing showed a positive response to Ti ($SI = 6.9$), while responses to the other metals

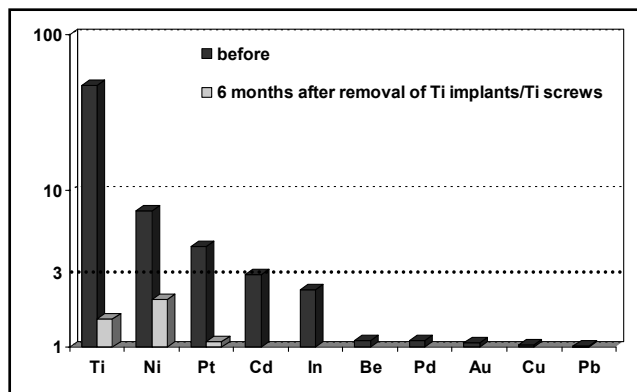


Figure 2. MELISA® reactivity in a 54-year-old man before and after removal of Ti-based dental implants and screws. See text for details. X-axis: metals tested; y-axis: Stimulation Index ($SI \geq 3$ positive).

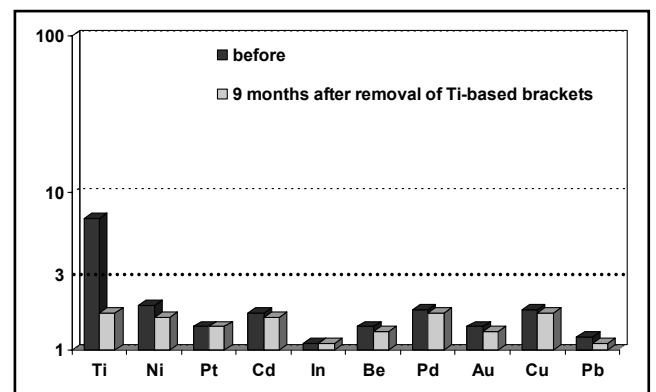


Figure 3. MELISA® reactivity in a 14-year-old girl before and after removal of Ti-based brackets. See text for details. X-axis: metals tested; y-axis: Stimulation Index ($SI \geq 3$ positive)

tested, including Ni, were negative. Patch testing to Ti was negative. The brackets were removed and replaced with a metal-free synthetic material. Toothpaste containing TiO₂ (E171) was avoided. Within nine months the facial lesions healed almost completely (slight postinflammatory hyperpigmentation remained), and the patient was once again healthy and active. Her lymphocyte reactivity to Ti normalized (SI = 1.7).

Patch testing

All 54 patch-tested patients were negative to Ti.

Discussion

In this study we investigated the potential of Ti to induce hypersensitivity or other immunological dysfunctions. The 56 patients described here all developed severe health problems after receiving Ti-based dental and/or endoprosthetic implants. Removal of the Ti-based devices, in most cases with no additional therapy such as chelation, led to remarkable recovery within six to nine months. In those patients previously reactive to Ti in MELISA® from whom follow-up samples could be obtained, all showed negative reactivity post removal, as described in detail for two typical cases. In all cases, however, patch testing for Ti was negative.

These results demonstrate two important facts. First, while Ti generally appears to be biocompatible for most individuals, a certain subgroup of people seems to be capable of developing a clinically-relevant hypersensitivity to this metal. Sporadic reports supporting this concept have been published since the 1980s, most of which, however, have lacked laboratory evidence both pre- and post-implant removal [1, 3, 13, 18, 27, 32, 33]. Recently, Thomas et al. [28] demonstrated LTT reactivity to Ti in a patient suffering from impaired fracture healing and eczema following implantation of a Ti miniplate and screws; both clinical symptoms and LTT reactivity decreased after removal of the implant. Several similar cases are described by Valentine-Thon et al. in a concomitant article in this issue [31].

To explain this apparent sensitivity to Ti, several hypotheses have been proposed. Under unfavorable conditions (acidic pH, mechanical friction, close contact to amalgam or gold restorations, etc.), Ti implants may corrode and release ions or micro-particles which can induce inflammation in affected tissues [4, 8, 9, 11, 14, 35]. This mechanism has been suggested to play a role in the loosening of implants [17]. Furthermore, Ti, like other transition metals, has a high affinity to proteins; Ti-bound cell membrane proteins (neo-antigens) may induce autoimmune reactions, whereas Ti-bound intra-cellular proteins may disrupt normal cell physiology [26]. Finally, Ti has been reported to activate macrophages, either directly or subsequent to phagocytosis [14, 17]. The *in vitro* phagocytic uptake of Ti by macrophages was clearly shown in this study (Fig. 1). Such activated macrophages may secrete both pro- and anti-inflammatory cytokines,

an imbalance of which has been implicated in various disease processes [5, 20].

Alternatively, in those symptomatic Ti-exposed patients who did not show hypersensitivity (MELISA® reactivity) to Ti, the possibility of an immune reaction to contaminating metals must be considered. In this study, 57.9% of such patients reacted to other metals, including Ni. As reported by Schuh et al. [21], Ti alloys may contain low levels of Ni which can induce or exacerbate allergic reactions. In a case described by Valentine-Thon et al. [31], a Ni-allergic patient developed chronic severe joint pain after inadvertently receiving a Ni-containing Ti knee endoprosthesis. In MELISA® her lymphocytes reacted strongly to Ni but not at all to Ti. After explantation, her lymphocyte reactivity to Ni decreased and her pain subsided. Four similar cases of Be-contaminated Ti implants have likewise been observed (Müller, unpublished data).

The second fact demonstrated by the results of this study is the current inadequacy of patch testing for detecting sensitivity to Ti. Only very few studies have reported a positive patch test result with Ti, one of which combined Ti in an ointment to facilitate dermal penetration [13]. As patch testing has been validated only for dermally-sensitizing antigens, its relevance for systemically-sensitizing antigens, such as Ti (mucosal) or Be (aerosol), will be limited. In the USA, the "golden standard" for detecting a type IV hypersensitivity to Be is not patch testing but a Be-lymphocyte proliferation test [22]. In analogy, the standardized and validated MELISA® Test, accredited in Germany since 2001, should be considered for patients with suspicion of Ti allergy.

In conclusion, the data presented here demonstrate that Ti can induce clinically-relevant hypersensitivity and other immune dysfunctions in certain patients chronically exposed to this reactive metal. Ti should no longer, therefore, be considered biologically inert.

Acknowledgement

The authors are grateful to Dr. Antje Kakuschke for the photographs in Figure 1.

REFERENCES

- 1 Abdallah HI, Balsara RK, O'Riordan AC. Pacemaker contact sensitivity: clinical recognition and management. *Ann Thorac Surg.* 1994; **57**: 1017-1018.
- 2 Bartram F, Donate H-P, Müller K, Bückendorf C-H, Ohnsorge P, Huber W et al. Significance of the patch test and the lymphocyte transformation test in the diagnostics of type IV sensitization. Statement of the German Professional Association for Environmental medicine (in German with English abstract). *J Lab Med.* 2006; **30**: 101-106.
- 3 Berglund F, Carlmark B. Yellow nail syndrome in patients with titanium and gold implants. *Toxicol Letters.* 1999; **51**: 53.
- 4 BiancoPD, Ducheyne P, Cuckler JM. Local accumulation of titanium released from a titanium implant in the absence of wear. *J Biomed Mater Res.* 1996; **31**: 227-234.
- 5 Dörner T, Haas J, Loddenkemper C, von Baehr V, Salama A. Implant-related inflammatory arthritis. *Nature Clin Practice.* 2006; **2**: 53-56.

- 6 Hallab N, Merritt K, Jacobs JJ. Metal sensitivity in patients with orthopaedic implants. *J Bone Joint Surg Am*. 2001; **83**: 428–436.
- 7 Halpern B, Amache N. Diagnosis of drug allergy *in vitro* with the lymphocyte transformation test. *J Allergy*. 1967; **40**: 168–181.
- 8 Holgers KM, Thompson P, Tjellström A. Persistent irritation of the soft tissue around an osteointegrated titanium implant. Case report. *Scand J Plast Reconstr Surg Hand Surg*. 1994; **28**: 225–230.
- 9 Huang HH, Chiu YH, Lee TH, Wu SC, Yang HW, Su KH et al. Ion release from NiTi orthodontic wires in artificial saliva with various acidities. *Biomaterials*. 2003; **24**: 3585–3592.
- 10 Kasemo B, Lausmaa J. Biomaterials and interfaces. Naert I, van Steenberghe D, Worthington P. *Osseointegration in oral rehabilitation*. Quintessence, London 1993; 63–75.
- 11 Katou F, Andoh N, Motegi K, Nagura H. Immuno-inflammatory responses in the tissue adjacent to titanium miniplates used in the treatment of mandibular fractures. *J Craniomaxillofac Surg*. 1996; **24**: 156–162.
- 12 Koch P. Kontakallergien bei Metallarbeitern (in German). *Dermatosen Occup Environ*. 1996; **44**: 62–67.
- 13 Lalor PA, Revell P, Gray AB, Wright S, Railton GT, Freeman MA. Sensitivity to titanium: A cause of implant failure? *J Bone Joint Surg Br*. 1991; **73**: 25–28.
- 14 Mayer W, von Baehr V, Frank I, Bieger W. Titan: Garant für Biokompatibilität oder potentiell Allergen? (in German with English abstract) *Z Umwelt*. 1999; **4**: 224–230.
- 15 Müller K. BfArM verfolgt Strategien der Vergangenheit (in German). *Z f Umweltmed*. 2002; **3**: 128–133.
- 16 Müller KE. Zwei Episoden eines Guillain-Barré-Syndrom (GBS) nach Roxithromycin und Mercurius solubilis (in German). *Umwelt Medizin Gesell*. 2003; **16**: 101–102.
- 17 Nakashima Y, Sun D-H, Trindade M, Maloney W, Goodman S, Schurman D et al. Signaling pathways for tumor necrosis factor- α and interleukin-6 expression in human macrophages exposed to titanium-alloy particulate debris *in vitro*. *J Bone Joint Surg*. 1999; **81**: 603–615.
- 18 Peters MS, Schroeter AL, van Hale HM, Broadbent JC. Pacemaker contact sensitivity. *Contact Dermatitis*. 1984; **11**: 214–218.
- 19 Prochazkova J, Sterzl I, Kucerova H, Bartova J, Stejskal V. The beneficial effect of amalgam replacement on health in patients with autoimmunity. *Neuroendocrinol Lett*. 2004; **25**(3): 211–8.
- 20 Roitt I, Brostoff J, Male DK, editors. *Immunology*, 6th Edition, London, Philadelphia, Sydney: Mosby, Inc; 2001.
- 21 Schuh A, Thomas P, Kachler W, Göske J, Wagner I, Holzwarth U et al. Allergic potential of titanium implants. *Orthopade*. 2005; **34**: 327–333.
- 22 Stange AW, Furman FJ, Hilmas DE. The beryllium lymphocyte proliferation test: relevant issues in beryllium health surveillance. *Am J Ind Med*. 2004; **46**: 453–462.
- 23 Stejskal VDM, Forsbeck M, Nilsson R. Lymphocyte transformation test for diagnosis of isothiazolinone allergy in man. *J Invest Dermatol*. 1990; **94**: 798–802.
- 24 Stejskal VDM, Cederbrant K, Lindvall A, Forsbeck M. MELISA – an *in vitro* tool for the study of metal allergy. *Toxicol in Vitro*. 1994; **8**: 991–1000.
- 25 Stejskal VD, Danersund A, Lindvall A, Hudecek R, Nordman V, Yaqob A et al. Metal-specific lymphocytes: biomarkers of sensitivity in man. *Neuroendocrinol Lett*. 1999; **20**: 289–298.
- 26 Stejskal VD, Hudecek R, Stejskal J, Sterzl I. Diagnosis and treatment of metal-induced side-effects. *Neuro Endocrinol Lett*. 2006; **27**(Suppl1): 7–16.
- 27 Tamai K, Mitsumori M, Fujishiro S, Kokubo M, Ooya N, Nagata Y et al. A case of allergic reaction to surgical metal clips inserted for postoperative boost irradiation in a patient undergoing breast-conserving therapy. *Breast Cancer*. 2001; **8**: 90–92.
- 28 Thomas P, Bandl W-D, Maier S, Summer B, Przybilla B. Hypersensitivity to titanium osteosynthesis with impaired fracture healing, eczema, and T-cell hyperresponsiveness *in vitro*: case report and review of the literature. *Contact Dermatitis*. 2006; **55**: 199–202.
- 29 Valentine-Thon E, Schiwara H-W. Validity of MELISA® for metal sensitivity. *Neuroendocrinol Lett*. 2003; **24**: 57–64.
- 30 Valentine-Thon E, Sandkamp M, Müller K, Guzzi G, Hartmann T. Metallsensibilisierung: Nachweis, Validierung und Verlaufskontrolle mittels Lymphozyten-Transformations-Test (LTT-MELISA®) (in German). *Zs f Orthomol Med*. 2005; **1**: 12–15.
- 31 Valentine-Thon E, Muller KE, Guzzi G, Kreisel S, Ohnsorge P, Sandkamp M. LTT-MELISA® is clinically relevant for detecting and monitoring metal sensitivity. *Neuro Endocrinol Lett*. 2006; **27**(Suppl1): 17–24.
- 32 Verbov J. Pacemaker contact sensitivity. *Contact Dermatitis*. 1985; **12**: 173.
- 33 Viraben R, Boulinguez S, Alba C. Granulomatous dermatitis after implantation of a titanium containing pacemaker. *Contact Dermatitis*. 1995; **33**: 437.
- 34 Warrington RJ, Tse KS. Lymphocyte transformation studies in drug hypersensitivity. *Can Med Assoc J*. 1979; **120**: 1089–94.
- 35 Weingart D, Steinemann S, Schilli W, Strub JR, Hellerich U, Assenmacher J et al. Titanium deposition in regional lymph nodes after insertion of titanium screw implants in maxillofacial region. *Int J Oral Maxillofac Surg*. 1994; **23**: 450–452.